

TREATMENT OF CERVICAL DISC HERNIATION

BACKGROUND

The cervical spinal cord may be considered the most important segment of the spinal cord, surpassing the thoracic and lumbar spinal segments. A herniated cervical disc is diagnosed when the inner core of a disc in the neck protruded, or leaks out of the disc, and presses on an adjacent nerve root. A cervical disc herniation may occur suddenly from trauma, but most often it occurs over time from chemical and mechanical degenerative changes.

HISTORY

A 44 years old woman has severe pain in his neck and left arm for 15 days. Neck pain on the right side of the nape. Her pain is strong enough to keep her from doing business (VAS 10). She was diagnosed as cervical disc herniation. The patient was advised to undergo surgery due to the negative impact of signs and symptoms upon her health. The patient agreed to surgery.


DIAGNOSIS

She was diagnosed with cervical disc herniation. It usually develops in the 30-to-50-year-old age group. While a cervical herniated disc may originate from some sort of trauma or neck injury, the symptoms commonly start spontaneously. The arm pain from a cervical herniated disc results because the herniated disc material pinches or presses on a cervical nerve, causing pain to radiate along the nerve pathway down the arm.



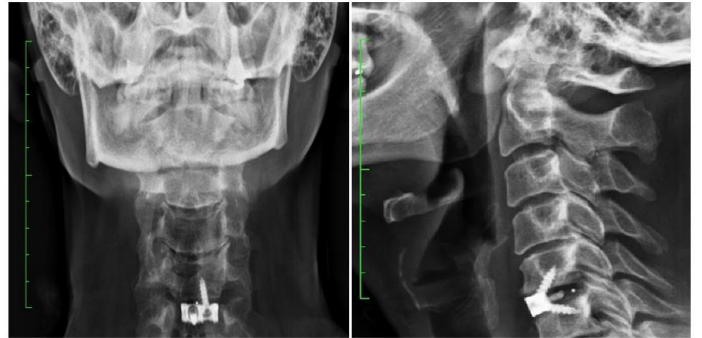
TREATMENT

The patient underwent C5-6 anterior cervical discectomy. Surgery was conducted using a standard anterior cervical approach and microdiscectomy. Under general anesthesia, the patient was placed in the supine position with the neck slightly extended. Through a right cervical incision, the target segment was exposed with the assistance of intraoperative C-arm X-ray. The anterior longitudinal ligament was opened, and the discectomy procedure was then performed. After sufficient decompression, an appropriately sized OSIMPLANT TITANOPEEK Stand Alone Cervical Cage was implanted into the intervertebral space under X-ray monitoring.



Prof. Dr. Uygur Er

POST-OPERATIVE IMAGES



CONCLUSION

The patient noticed a significant improvement in the amount of left arm and neck pain. All complaints of the patient were eliminated. OSIMPLANT ARION Expandable Bladed Cervical Cage can be used safely to obtain fusion after anterior cervical discectomy. The outcomes of this case indicate that OSIMPLANT TITANOPEEK Stand Alone Cervical Cage is an effective technique for treating degenerative cervical disc disease.